

UofT LMP Head and Neck Pathology COI – Nov 2024 Meeting Interesting Cases

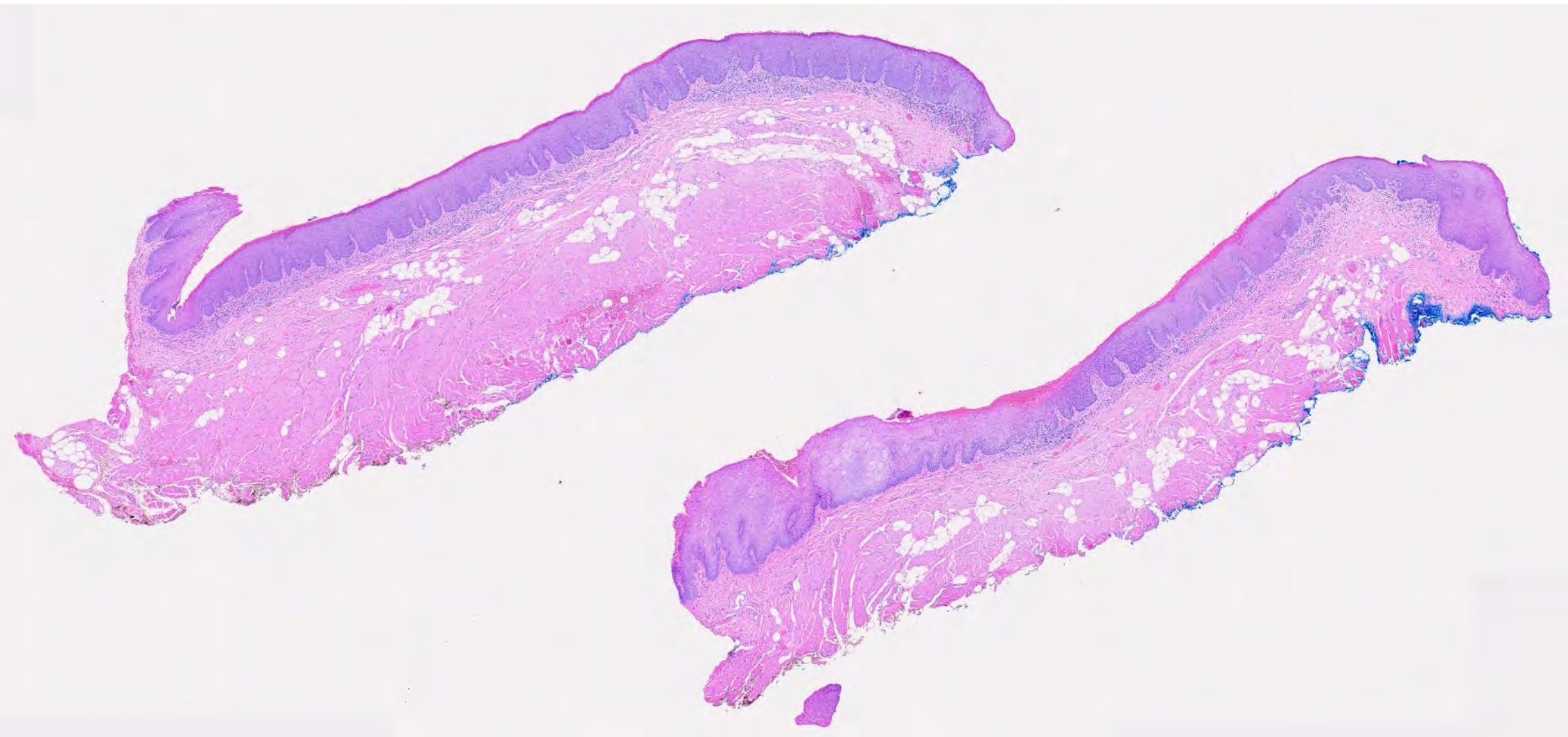
The theme of our November COI meeting is oral epithelial dysplasia.

We prepared some interesting cases for discussion. Please review the representative images below, and consider the following questions:

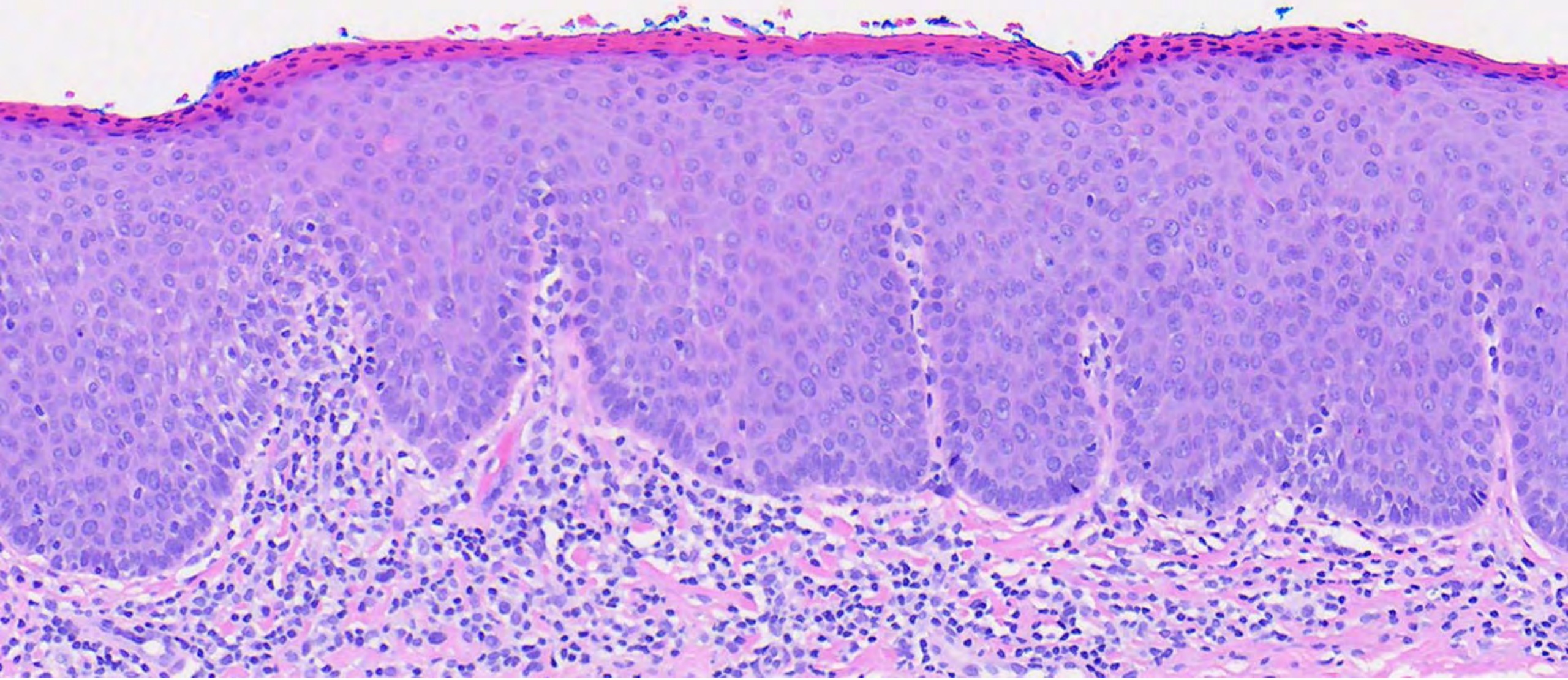
- (1) Is this OED or reactive?
- (2) How would you grade the dysplasia?
- (3) Based on the morphology, can you make a prediction of the mutation/HPV status?

At the meeting, you will have the chance to review whole slide scanned images and participate in an anonymous poll.

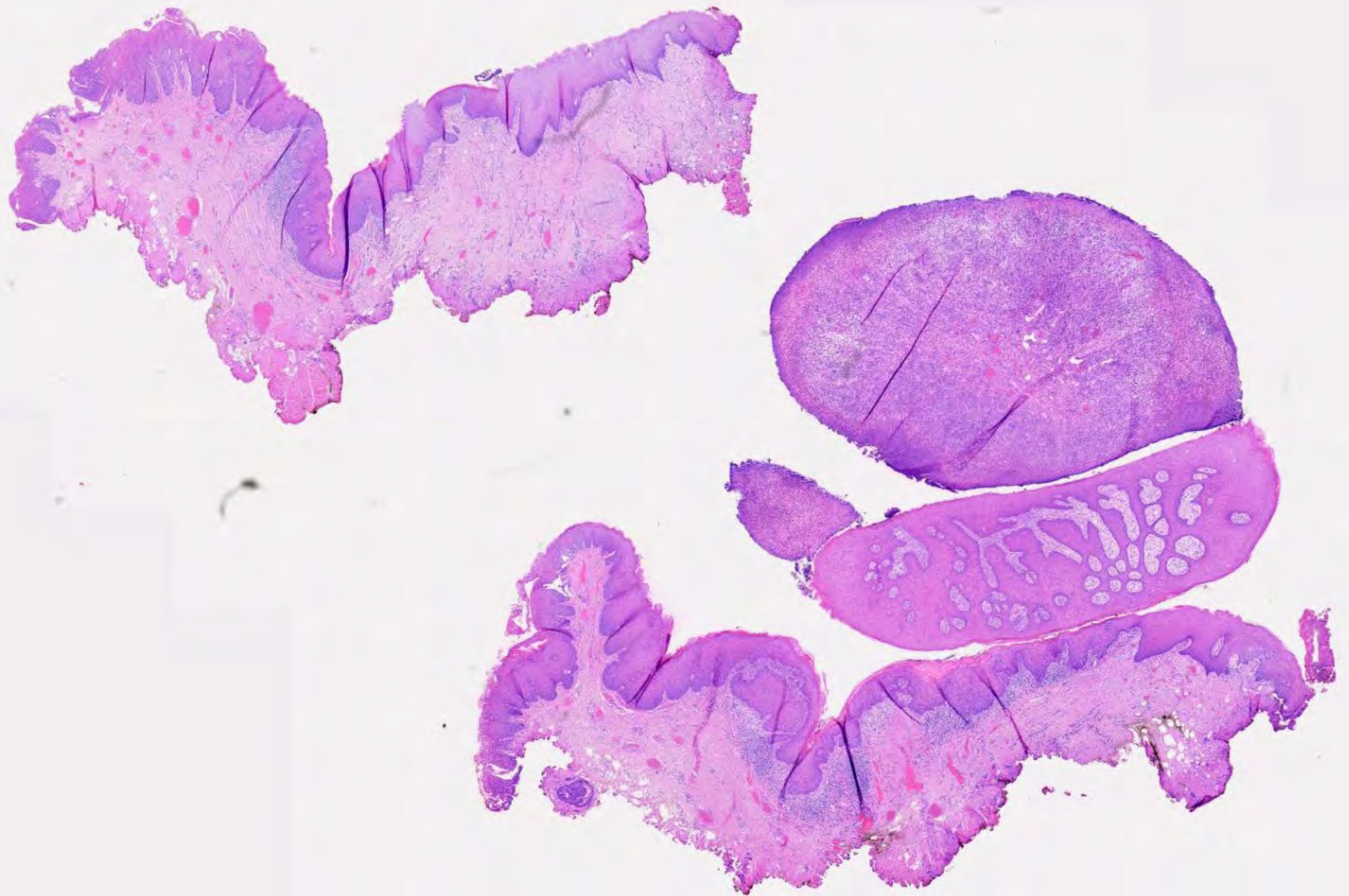
OED #1 Lower power



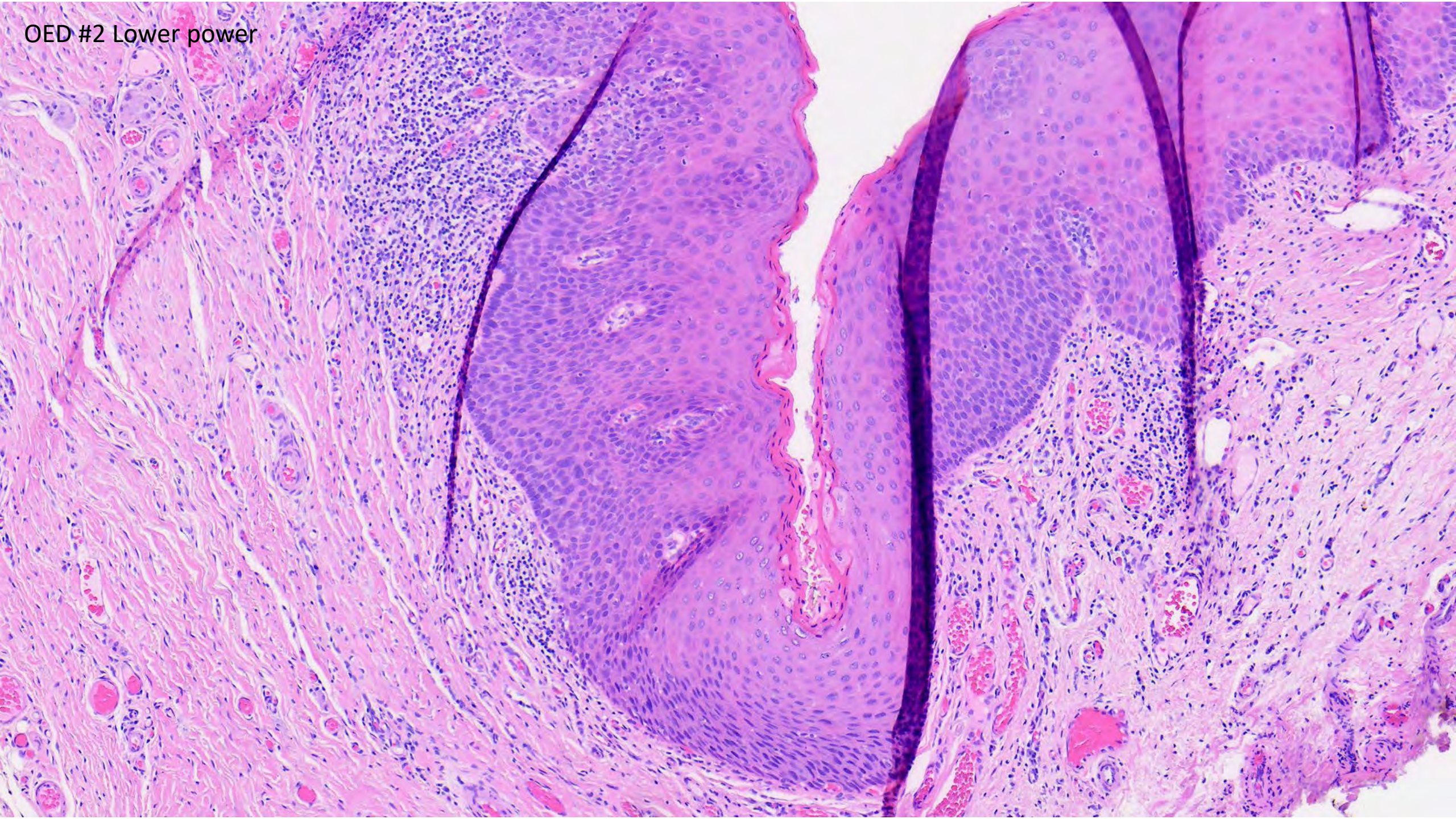
OED #1 High power



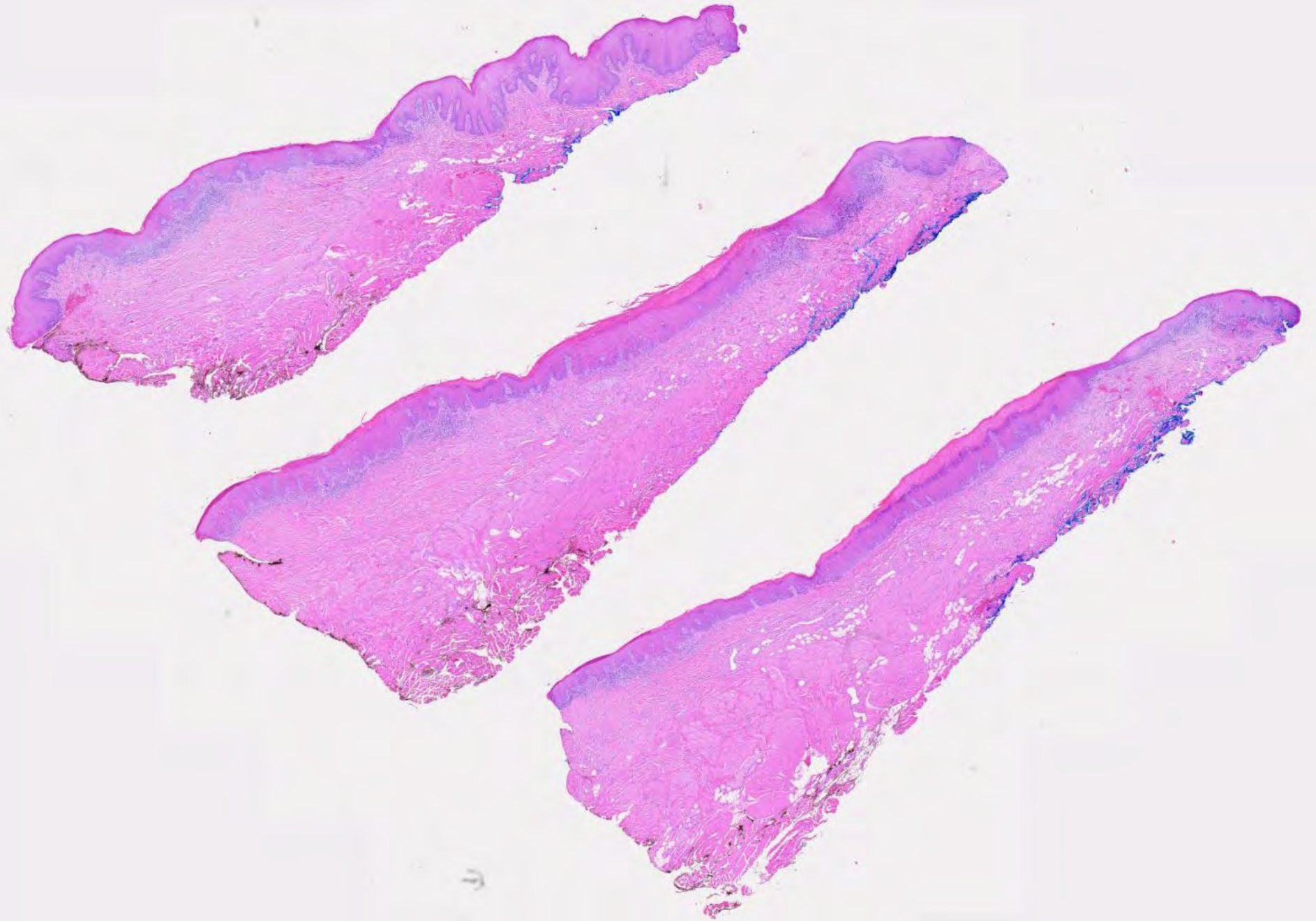
OED #2 Lower power



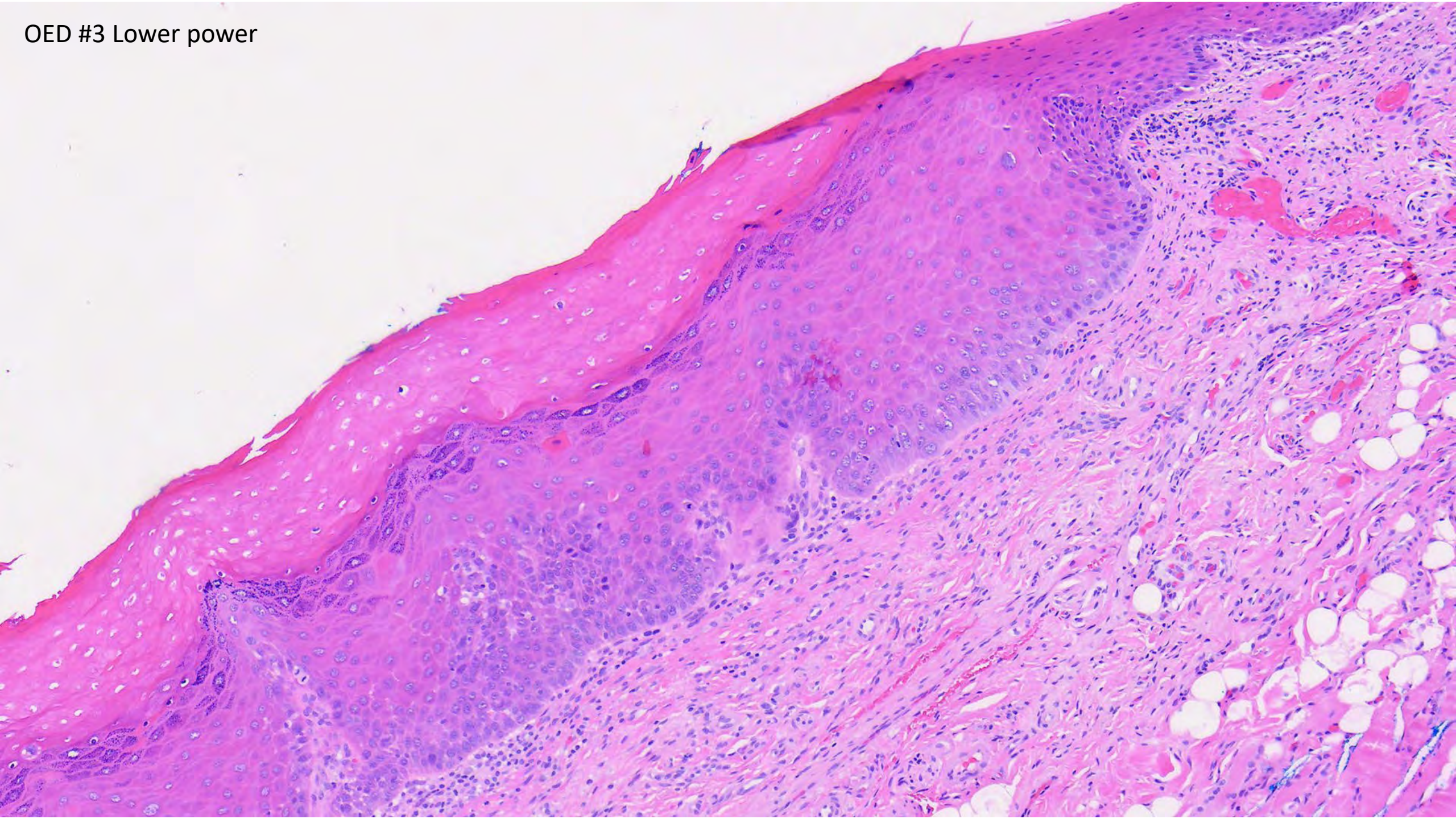
OED #2 Lower power



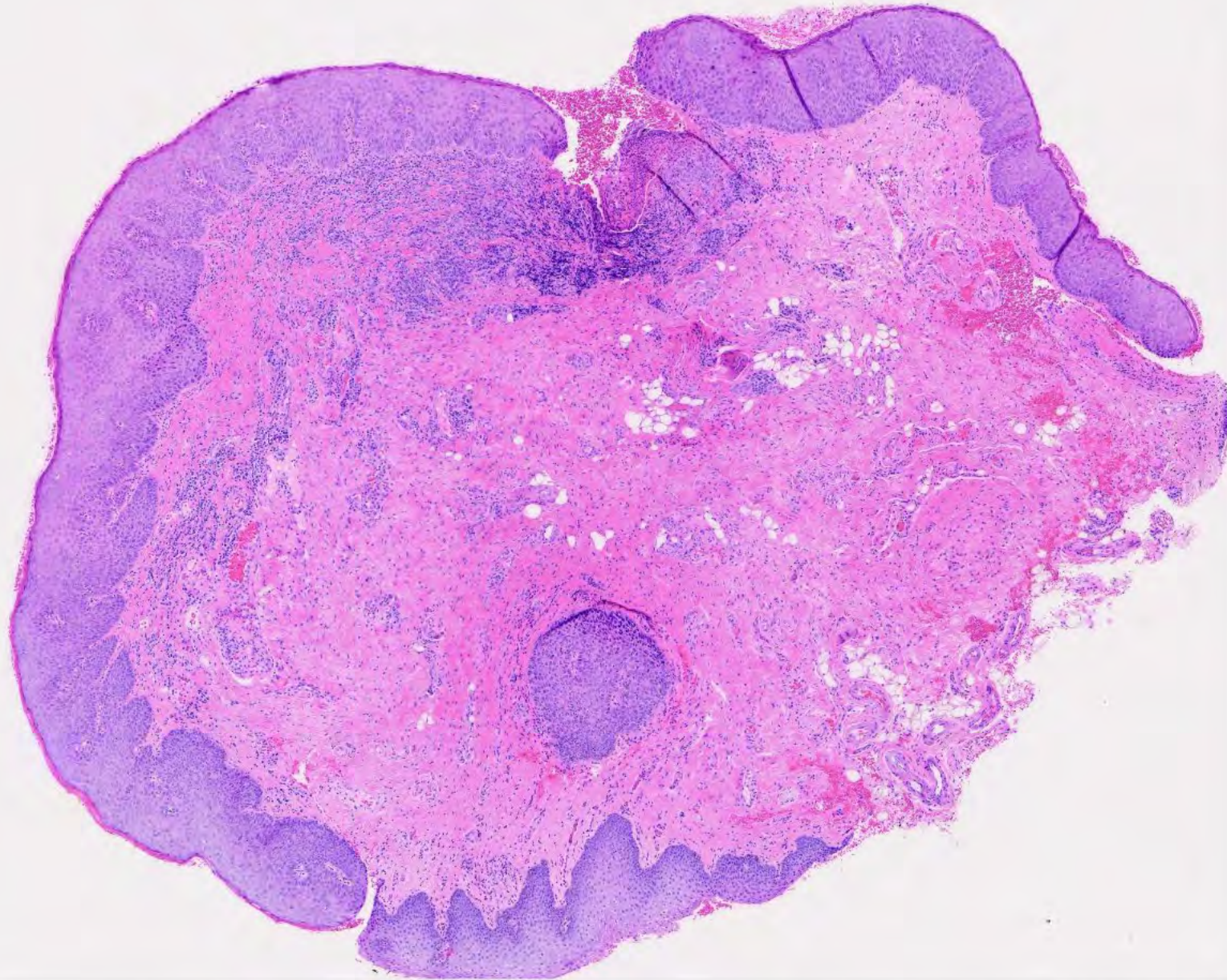
OED #3 Lower power



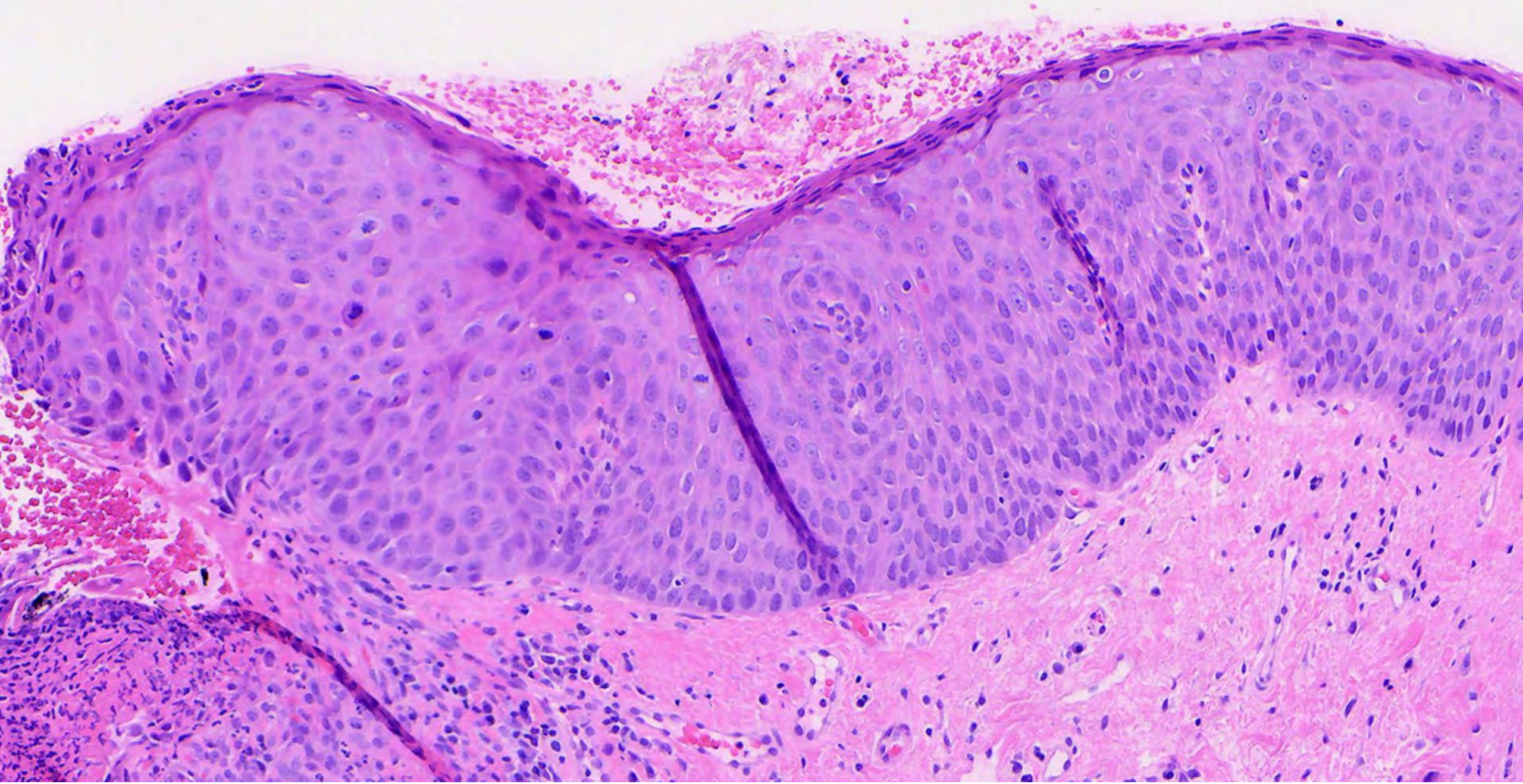
OED #3 Lower power



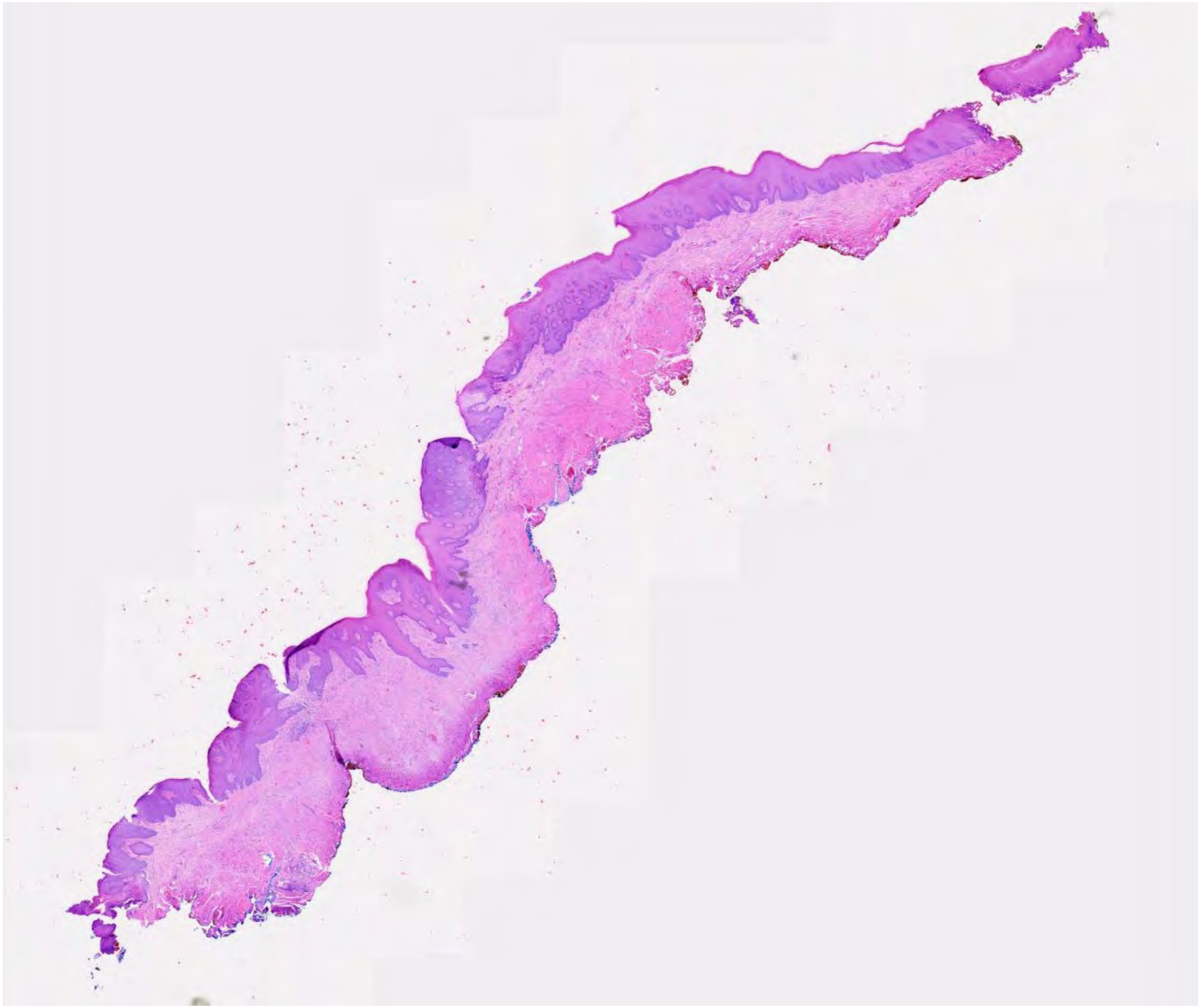
OED #4 Lower power



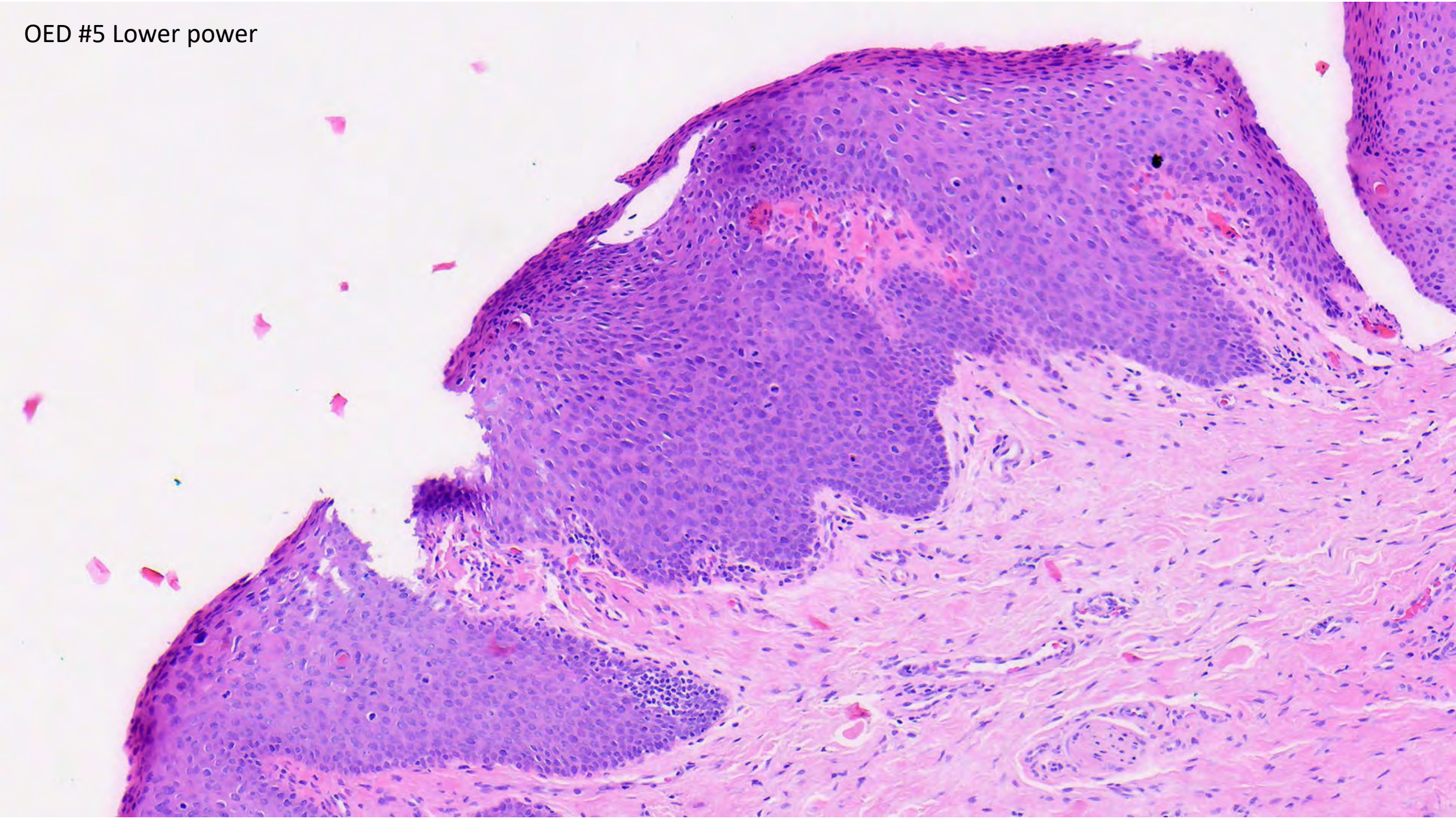
OED #4 Lower power



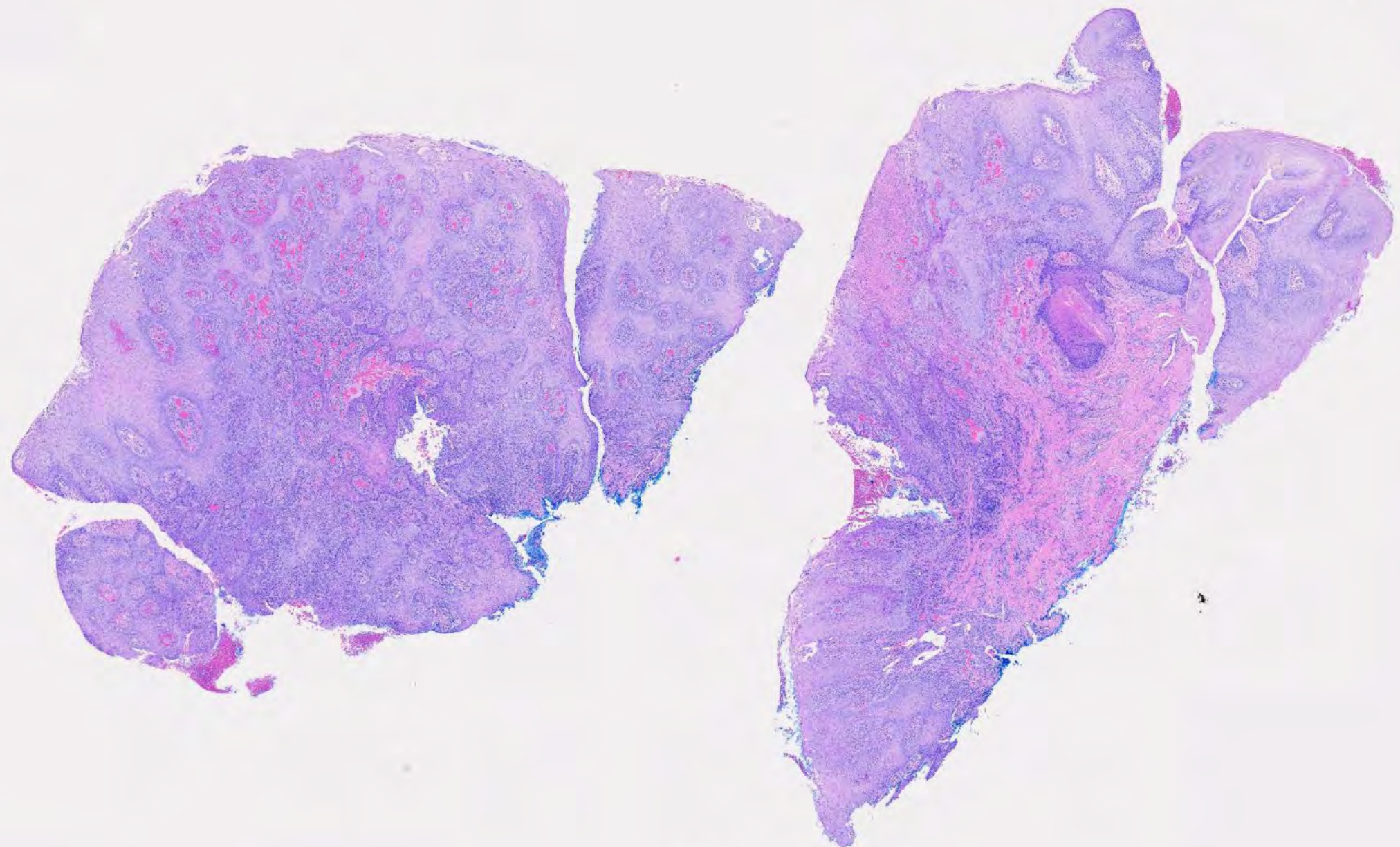
OED #5 Lower power



OED #5 Lower power



OED #6 Lower power



OED #6 Lower power

